

BACKGROUND

Three ostomates (2 with ileostomy, 1 with colostomy) were admitted with Peristomal Moisture Associated Dermatitis (PMAD) were cared for by the WOC Nurse team in the hospital.

Peristomal Moisture Associated Dermatitis is inflammation and denudation of skin adjacent to a stoma associated with exposure to effluent, such as urine or stool. (ncbi.nlm.nih.gov) PMAD is painful to skin and challenging in pouching management due to skin erosion that affect wear time. Varieties of skin management were tried until we found moisture skin products that heals the affected area and improved the pouching system wear time and pain reduction.

PURPOSE of Innovation

Multiple moisture skin products failed to accomplish wear time of more than 24 hours.

Patients were having difficulty engaging in activities due to pain and frequent pouch leakage issues.

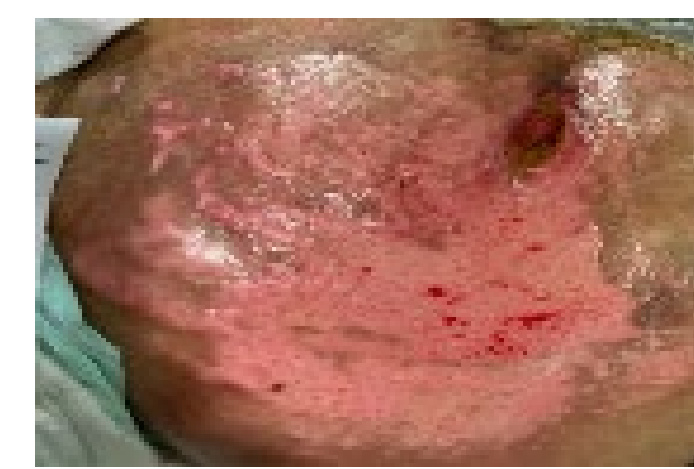Patients were anxious to achieve a better quality of life upon discharged.

REFERENCES

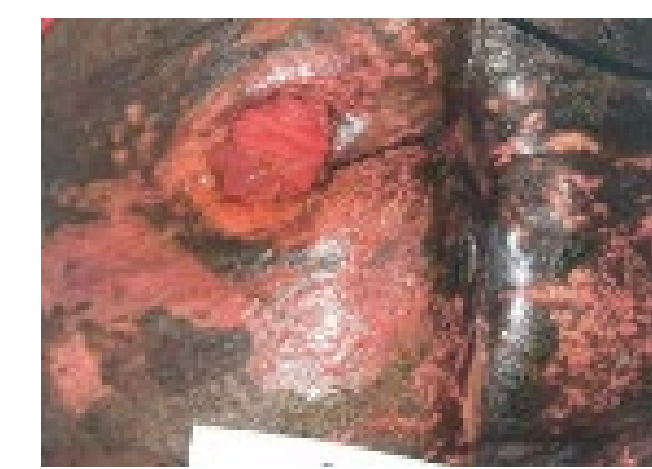- 1.Emory University Nell Hodgson Woodruff School of Nursing. Wound Ostomy & Continence Nursing Education Program (2016) Section XII Peristomal Skin Care and Pouching Guidelines. Ostomy And Continent Diversions Core Content (pp126-138)
- 2.Goldberg, Margaret. Patient Education Following Urinary/Fecal Diversion. Wound Ostomy Continence Nurses Society Core Curriculum. Ostomy Management. 2016 Chapter 11 pp131-138.
- 3.Gray, M, Black JM, Baharestani MM, et al. Moisture Associated Skin Damage: Overview and pathophysiology. J Wound Ostomy Continence Nursing 2011; 38(3):233-241

METHODS

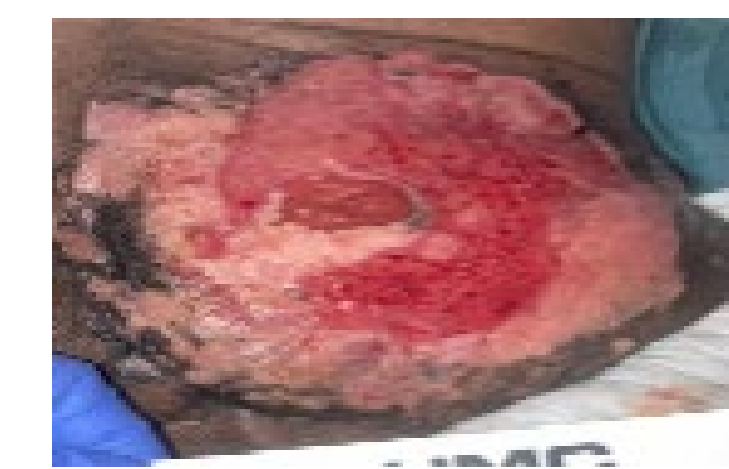Peristomal Moisture Associated Dermatitis noted on peristoma and surrounding skin. (Day 1)



(1)Ileostomy



(2) Ileostomy

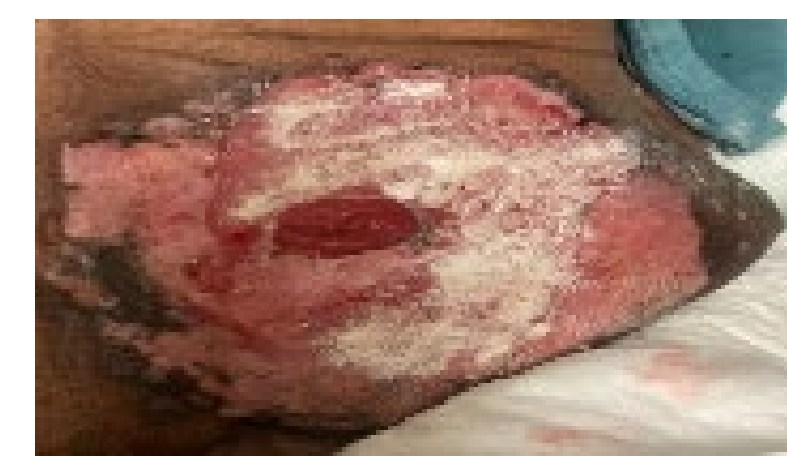

(3) Colostomy

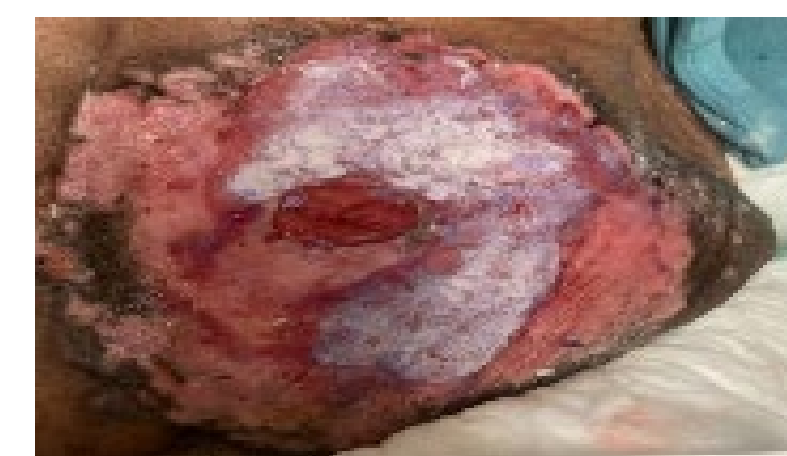Application of crusting method (by using stoma powder and no sting barrier film) and no sting cyanoacrylate skin protectant.

Innovation Process:

(1) After cleaning the affected skin with warm water then patted dry, apply stoma powder, then dust away excess powder, seal the powder with no sting barrier wipe by pressing over the powder, repeat 1 to 2 times. Let it dry.



(2) Apply No sting cyanoacrylate skin protectant over the area with powder and reddened area.



Pouch was applied after the Innovation process.

Patients and family members taught crusting method and application of no sting cyanoacrylate skin protectant and proper management of creases and uneven abdominal terrain to heal the PMAD and achieve 3-4 days wear time with rare leak. Patient taught to empty if it is 1/3 to 1/2 full or full of gas in order for the pouch to be light at all times, hence, decrease pouch pulling from skin and leakage.

Products Used:



Stoma powder



No sting barrier wipe



No sting cyanoacrylate skin protectant

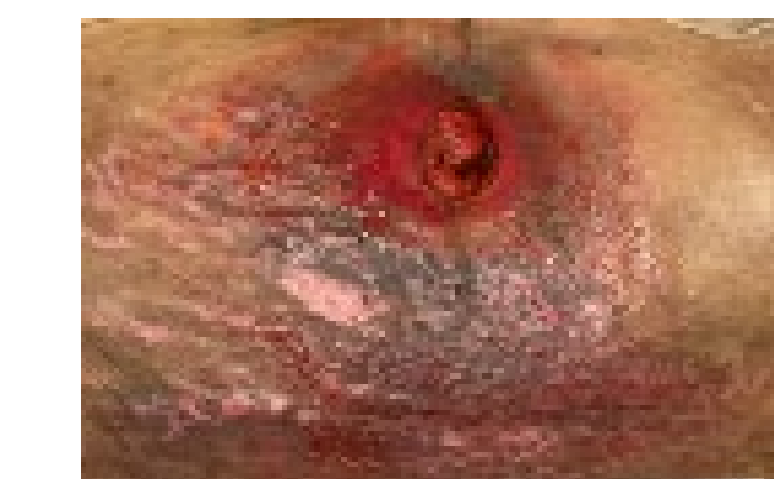RESULTS

Ultimately, an approach that involved application of crusting method (by using stoma powder and no sting barrier film) and no sting cyanoacrylate skin protectant heals the PMAD and it achieved 3-4 days wear time and rare leaks.

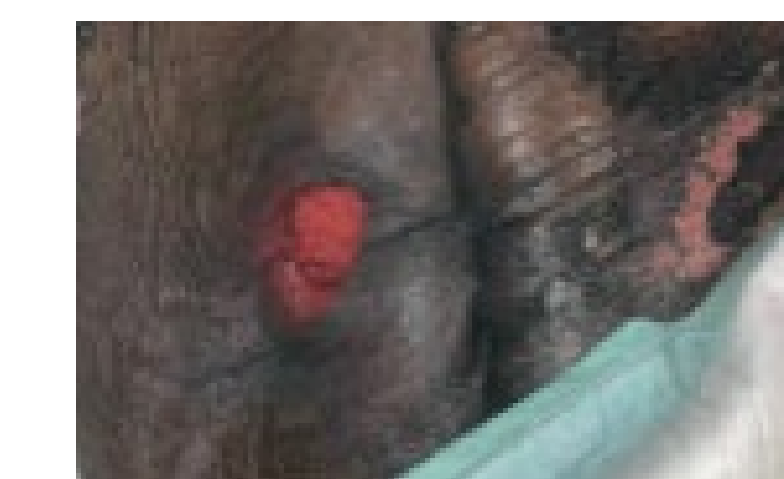
Teaching patients and family members the proper management of PMAD as well as creases and uneven abdominal terrain and importance of proper emptying helped achieved 3-4 days wear time of pouching system.

Patients' self esteem were improved and all of them had gained their confidence in engaging in hospital activities.

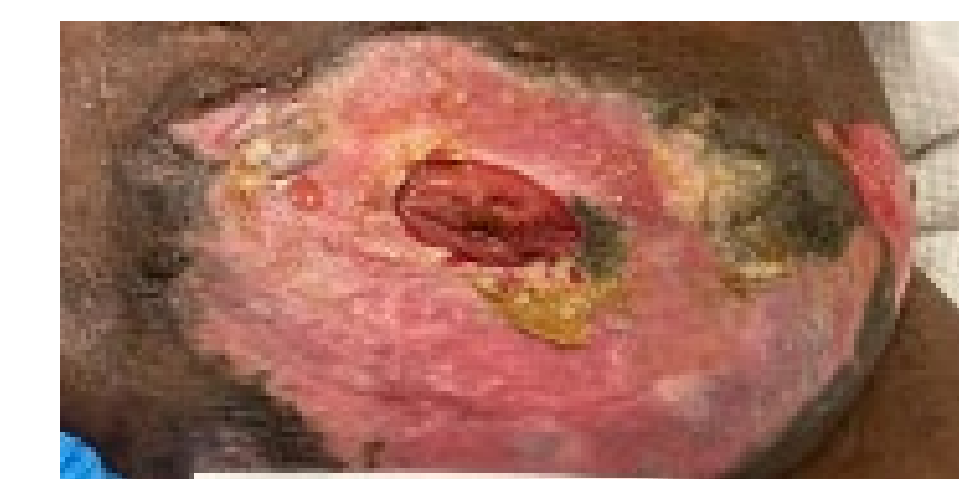
All 3 patients have not seen of same skin issues when re-admitted in the hospital.



(1) Day 14



(2) Day 7



(3) Day 10

CONCLUSIONS

Teaching patients and family members the proper management of Peristomal Moisture Associated Dermatitis by using crusting method and no sting cyanoacrylate skin protectant and management of creases and uneven abdominal terrain were keys to success to achieve 3-4 days wear time of pouching system.

Pain and pouch leakage issues were also reduced.

Patients also gained confidence in emptying own pouch and in engaging in hospital activities.

Patients' achieved a better quality of life upon discharged.

